

# Box Turtle Facial Inflammation Syndrome



Identifying and treating a common killer among wild box turtles.

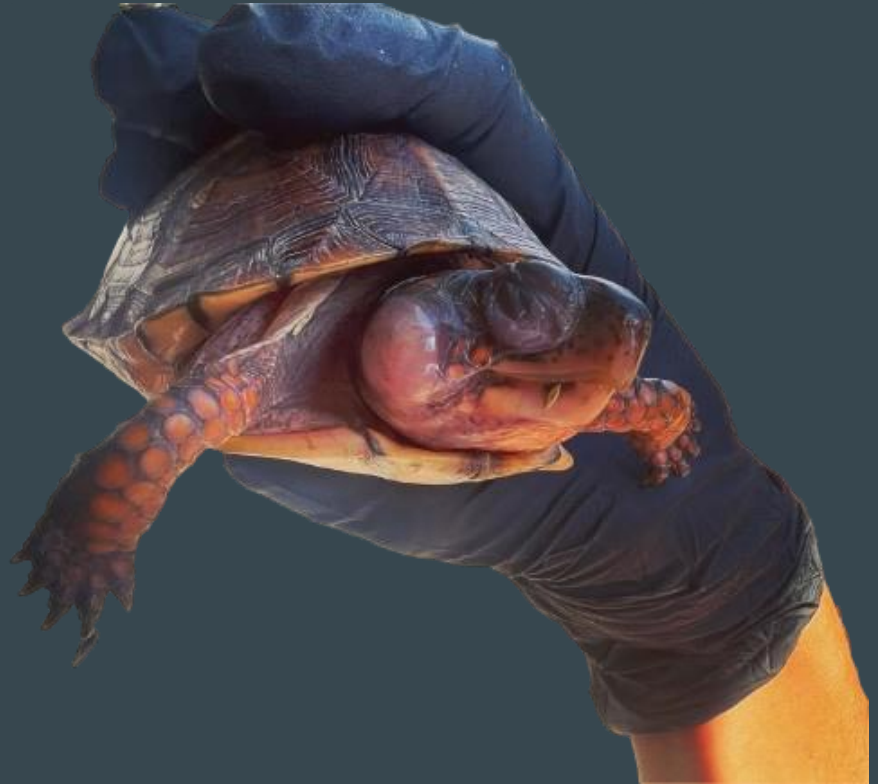Juniper Russo, CWR

# Box Turtle Facial Inflammation Syndrome

Characterized by inflammation and infections in the ears, eyes, and nose.

Linked to dietary vitamin A deficiency in captive turtles since 1967. (Elkan)

Associated with organochlorine pesticide exposure in wild box turtles since at least 1997. (Tangredi et al.)



# Symptoms of BTFIS

## Ears

Abscesses, which look like a bulge on the side of the head.

These can be quite large and are very painful. Some turtles will scratch or rub them.

## Eyes

Eyes may be swollen and kept closed most of the time.

There may be a cataract-like white film over the eyes.

White, yellow, or mucus-like discharge.

## Nose

Affected animals may have white nasal discharge or bubbles coming out of the nose.

Turtles with nasal symptoms tend to have and poor outcomes.

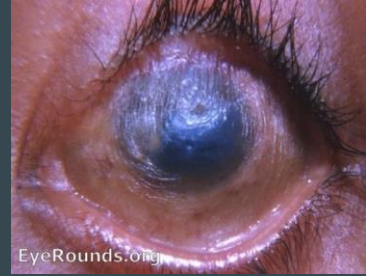
# What's Vitamin A Got to Do With It?

Vitamin A is critical for the proper function of the immune system and health of epithelial tissues of all vertebrates.

When deficient, animals (including humans) develop inflammation and in the eyes and ears and become more susceptible to infections.

Box turtles with BTFIS symptoms have low levels of vitamin A in their blood and livers.

Box turtles can absorb vitamin A from both retinoid (fat-soluble, animal-based) and carotenoid (water-soluble, plant-based) sources.

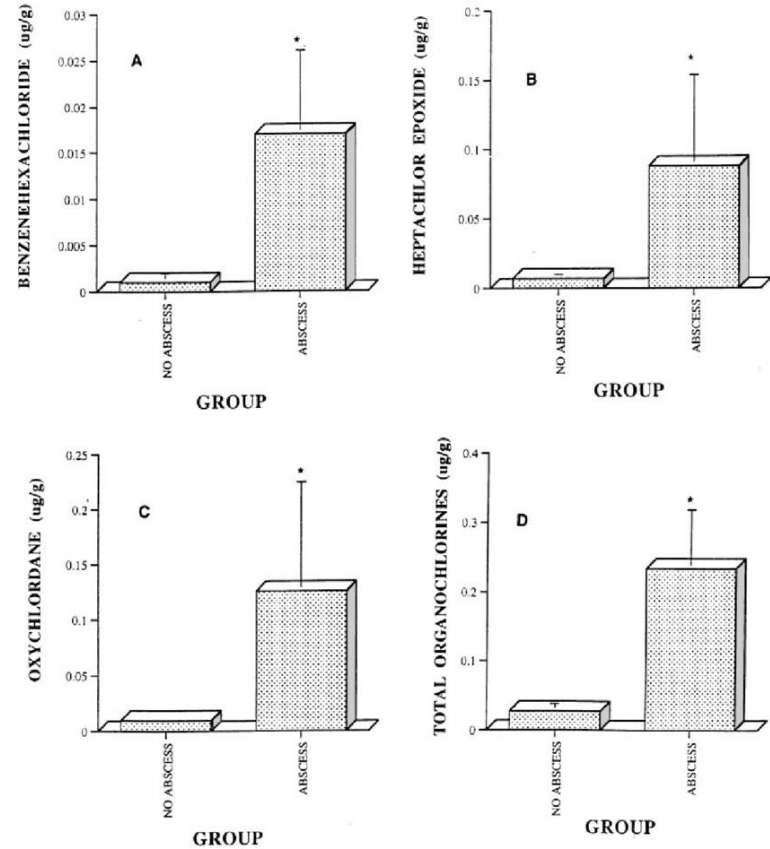


# The Link to Organochlorines

Organochlorines are a class of pesticides most notoriously including DDT. They are still used.

Wild box turtles with BTFIS have low levels of vitamin A and high levels of organochlorine pesticides. (Tangredi et al. 1997, Holladay et al. 2001, Sleeman et al. 2008)

This suggests that organochlorines reduce absorption or storage of vitamin A.



Holladay et al. 2001

# Treatment: Immediate Care

**\*\*WORK WITH YOUR VET!\*\***

Use PPE while handling. These turtles are immunocompromised.

General triage: overall exam, weight, photos.

Soak in water (good), saline (better), or LRS (best) for at least 8 hours.



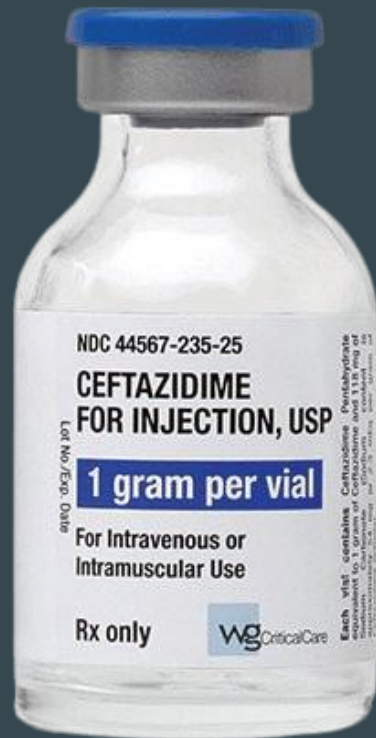# Treatment: Medication

**\*WORK WITH YOUR VET!\***

Ceftazedime is my vet's preferred antibiotic for BTFIS..

Neopolydex or tobramycin eye drops or ointment may be helpful.


Tramadol can be effective pain relief, especially for box turtles with large aural abscesses.



# Treatment: Vitamin A Supplementation

**\*WORK WITH YOUR VET!\***

Commercially available turtle eye drops generally contain vitamin A supplements. I have had success using them for BTFIS but it has been much slower than standard vitamin A supplements. The specific formula shown here is a low dose in a saline solution.



Vitamin A supplements made for humans can be used to create a supplement for turtles. You can carefully measure 1,000 IU and give PO weekly.

This is retinoid vitamin A in oil and can cause overdose if not careful.



# Treatment: Surgery

Large abscesses may need to be surgically drained.

Reptile pus is a solid and can't drain through a small hole. It requires a large C-shaped incision.

This is a surgery that requires sedation and sterile equipment and must be performed only by a veterinarian.

This patient has finders who attempted to “pop” her abscesses and nearly killed her. Here she is after proper surgery!



# General Husbandry

Excellent husbandry is especially important for these animals since they are immunocompromised.

Habitat should be very warm and well-lit, UV should be on about 14 hours per day to stimulate healing and appetite.

Substrate and water are important and must be very clean.

Emphasize carotenoids in diet: orange, red, yellow fruits and vegetables.



# Release Considerations

Patient should be asymptomatic for at least two weeks before release.

Potential for re-exposure to pesticides should not be used as a reason to relocate the animal.

I overwinter if not release-ready by November 15.

It may be helpful to ask the property owner to monitor the individual and keep an eye out for sick turtles— others are often found on the same property.



# 94.5%

of box turtles admitted at For Fox Sake with BTFIS have been released to the wild, out of 128 individuals. Time between admission and healing ranged from 6 weeks to 7 months.

**Questions?**

# Citations

Tangredi BP, Evans RH. 1997. Organochlorine pesticides associated with ocular, nasal, or otic infection in the eastern box turtle (*Terrapene carolina carolina*). *J Zoo Wildl Med.* 28:97-100.

Sleeman, JM, Brown J, Steffen D, Jones D, Roberston J, Holladay S. 2008. Relationships among aural abscesses, organochlorine compounds, and vitamin a in free-ranging eastern box turtles (*Terrapene carolina carolina*). *J Wildl Dis.* 44:922-9.

Holladay SD, Wolf JC, Smith SA, Jones DE, Robertson JL. 2001. Aural abscesses in wild-caught box turtles (*Terapene carolina*): possible role of organochlorine-induced hypovitaminosis A. *Ecotoxicol Environ Saf.* 48:99-106.

Elkan, E. and Zwart, P. (1967). the ocular disease of young terrapins caused by vitamin A deficiency . *Pathologia Veterinaria.* 4: 201-22.